

Rehabilitation of Down Syndrome with Zygomatic Implants-Case Report

Fernando Duarte^{1*}, Luis Pinheiro², Carina Ramos³ and João Neves Silva⁴

Affiliation:

¹Fernando Duarte, CEO and Clinical Director of Clitrofa - Trofa - Portugal

²Luis Pinheiro, Clinical Director of Cero - Lisbon - Portugal

³MSc student in Oral Oncology at Instituto de Ciências Biomédicas Abel Salazar - Oporto University - Portugal

⁴João Neves Silva, Professor at ISAVE - Instituto Superior de Saúde - Portugal

*Corresponding Author: Fernando Duarte, Clitrofa – Centro Médico, Dentário e Cirúrgico, Avenida de Paradela 626, 4785-342 Trofa – Portugal, Phone: (351) 252428960.

Received: December 28, 2020 Published: January 08, 2021

Abstract:

Purpose: Patients with Down syndrome may not be cooperative during dental treatment and, in cases of complex treatment, it is necessary to use oral or inhaled sedation and/or general anesthesia, which represent safe and efficient treatment resources. There are few reports about oral rehabilitation with dental implants, in patients with this condition in the literature.

Material and method: This paper will present a case report of Down syndrome treated with 2 zygomatic implants in the posterior maxilla and 2 standard axial implants in the anterior maxilla.

Result: The patient is on twelve months of postoperative without complaints.

Conclusion: The high survival rate, the increase of patients' demand in immediate functional ability and the less morbidity following the surgical procedure renders this zygomatic implant procedure a viable treatment option of the resorbed fully edentulous maxilla.

Keywords: Zygomatic implant, Down syndrome, Atrophic maxilla

Introduction

The literature with respect to dental implants in patients with neuro-psychiatric disorders is sparse and contradictory. Some case reports and case series have shown dental implants treatment to be successful in some patients with various degrees of both intellectual and physical disability, including cases of cerebral palsy, down syndrome, psychiatric disorders, dementia, bulimia, Parkinson disease and severe epilepsy ⁽¹⁾.

Advances in implantology have created choices to enhance the expectations of professionals and patients. There are more realistic options for restoration of function and esthetics regardless of age, and in most cases, medical disabilities, and can improve oral health and health-related quality of life ⁽²⁾.

Down syndrome (DS) is caused by the presence of a third copy of chromosome 21 (trisomy 21) and affects approximately 1 in every 700 children. DS is the leading cause of mental disability and with intellectual disability; also gives rise to a number of characteristic physical features, including characteristic facial features, diminished physical growth, and decreased fertility ⁽³⁾.

DS is frequently associated with complex difficulties in oromotor development, as feeding and/or swallowing, and is associated with an high incidence of oral motor impairments, feeding disorders, and dysphagia ⁽⁴⁾.

Dental and Facial Features

Dental characteristics such as delayed development and eruption of both dentitions, hypodontia, microdontia, short roots, hypocalcification-hypoplastic defects and occlusal problems exist for patients with DS. Along with mouth breathing and orofacial features such as flattened face and occiput, slanting eyes with prominent epicanthic folds, underdevelopment of the middle third of the face and prognathism ⁽⁵⁾.

Typical craniofacial characteristics are microcephalia, prominent epicanthic folds, a low general muscle tone and a hypoplastic maxilla. In comparison to the normal population, low muscle tone of the face and tongue are often present, causing the characteristic protrusion of the tongue. Maxillary growth remains reduced and aggravates the midface hypoplasia over the years, as hypoplastic maxilla, leading to a skeletal Class III tendency and reduced face height ⁽⁶⁾.

Parafunctional habits such as bruxism may also lead to an excessive attrition of teeth. Agenesis (or hypodontia) is 10 times more common in individuals with DS compared with systemically healthy patients and therefore, these patients require more frequent and earlier tooth replacement than the rest of the population ⁷.

Despite their physical and mental disabilities, life expectancy of individuals with DS ranges from 50 to 60 years of age, posing new challenges for dental providers to maintain optimum oral health care and restore function when the need arises ⁵. Removable and fixed prostheses supported by dental implants placed in the jaws may be provided to patients with DS for restoring masticatory function and esthetics ⁽⁷⁾.

Some patients with DS experience premature edentulism, which can lead to severe alveolar atrophy causing retention problems in purely mucosa-supported dentures and ill-fitting total dentures. The implant-supported total prosthetic restoration with bar joint has been well accepted by the patient and the patient's relatives ⁽⁸⁾.

The risk of soft tissue complications are higher among patients with neurological disabilities ⁽⁵⁾ and the cumulative survival rate of 85,8% for implants placed in individuals with congenital and neurological disabilities after 5 to 10 years ⁽⁹⁾, is lower when compared with survival rate of general population that is as high as 96% ⁽¹⁰⁾.

Individuals with DS often have parafunctional habits such as bruxism and tongue thrusting with studies suggesting that bruxism may contribute to early failures of immediately loaded dental implants. For this reason, it may be advisable to avoid immediate loading in DS patients ⁽⁷⁾.

Zygomatic Implant Concept

In the early 1990s, with his experience in animal and human research, PI Brånemark acknowledged that the introduction of implants in the maxillary sinuses did not necessarily compromise breath health. The use of the zygomatic bone as an anchorage point for implants, would ensure the prosthetic rehabilitation of mutilated patients, resulting from surgeries of tumor resection, trauma or congenital facial defects ^(11,12). As these interventions were successful and the long-term stability of these implants was verified, Brånemark developed the zygomatic implant, which provides bone fixation under conditions of severe resorption or bone loss in the posterior maxilla, with the advantage of eliminating the need for bone grafts in its intervention area ^(11,12,13).

The zygomatic implant design and placement protocols have been extensively described previously. In short, the implant, ranging from 32 mm to 62 mm, is introduced into the second premolar area, traversing the maxillary sinus and is anchored in the zygomatic bone. In addition to 2 zygomatic implants, 2 to 4 conventional implants are required in the anterior maxilla to support the prosthesis ^(14,15). Zygomatic implants have shown good clinical success rates in clinical studies, most often close to 100% success with follow-up periods of up to 5 years ^(16,17,18,19). Sinuscopy performed in patients with zygomatic implants has shown absence of infection or inflammation in the surrounding mucosa ⁽²⁰⁾. Furthermore, placement of four zygomatic implants in the same maxilla has also been reported to be a clinically successful treatment option, with similar complications to those experienced with the original technique ⁽²¹⁾.

Due to the high osseous density of zygoma bone and to the high clinical survival rates associated with zygomatic implants ^(16,17,18,19), this tissue/implant interface is particularly suitable for immediate function.

Clinical Case

A 32-year-old female patient, caucasian, attended the Oral-Maxillofacial Surgery consultation at Clitrofa - Centro Médico, Dentário e Cirúrgico, in Trofa - Portugal, to perform an implant-supported rehabilitation of the upper jaw.

The clinical evaluation reveals a DS patient with typical craniofacial characteristics namely: microcephalia, protuberant epicanthic folds, a low general muscle tone and a hypoplastic maxilla. The reduction in maxillary growth aggravates the midface hypoplasia, leading to a skeletal Class III tendency and reduced face height.

The dental evaluation reveals a partially edentulous jaw with the presence of teeth 1.4, 1.5, 1.6, 1.7, 1.8, 2.4, 2.5, 2.6, 2.7 and 2.8 which supported a removable prosthesis. The majority of teeth present periodontitis and high degree of mobility (Fig. 1).

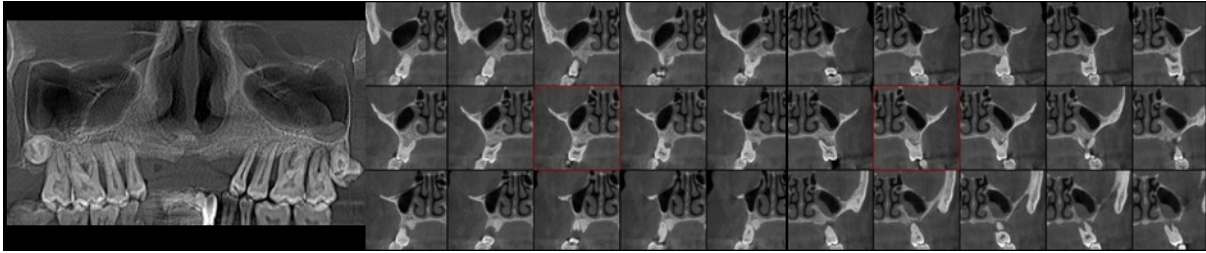


Fig.1 – Initial computed tomography with coronal and cross sections

After anamnesis, there was no allergies or use of medications. To complete the pre-surgical evaluation, high-definition computed tomography was performed, which revealed an extremely resorbed maxilla in the posterior sector. Clinical case with indication for placing 2 very angulated zygomatic implants in the posterior sector and 2 standard implants in the anterior sector of the maxilla (Fig. 2).

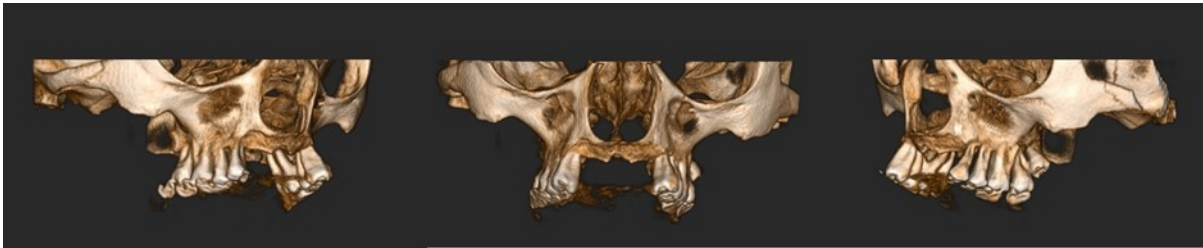


Fig.2 – Pre-operative 3D maxilla bone reconstruction

After full-thickness flap with bilateral identification of the infraorbital nerves, an osteotomy was performed to create a bone window to access the interior of the maxillary sinus. Maintenance of the relevant anatomical structures integrity and placement of the zygomatic implant in the ideal position for each clinical case are crucial. Zygomatic implants allowed to achieve an excellent primary stability as well as an adequate positioning for prosthetic rehabilitation (Fig. 3).

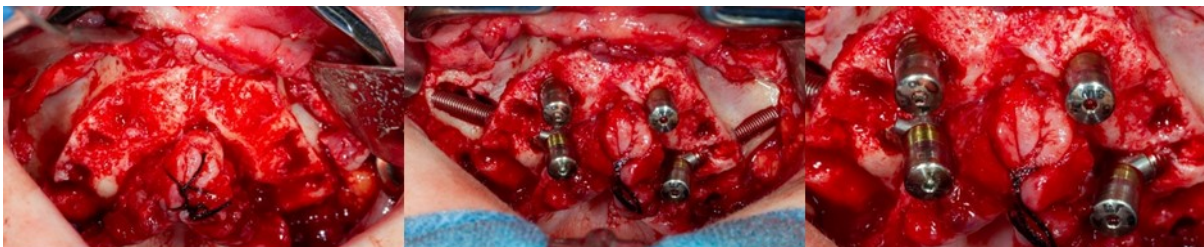


Fig.3 – Intraoperative aspect of implant placement

After completion of the surgery, a new high-definition computed tomography was performed to check the final position of the 2 zygomatic implants placed in the posterior sector of the maxilla and the 2 standard implants placed in the anterior sector of the maxilla (Fig. 4 and Fig. 5).

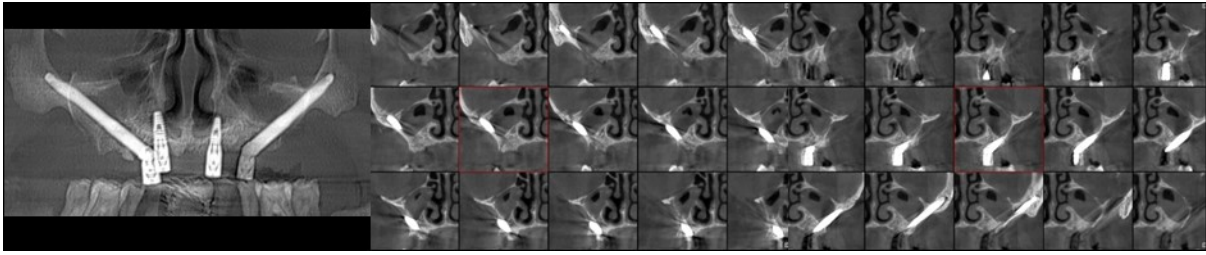


Fig.4 – Final computed tomography with coronal and cross sections

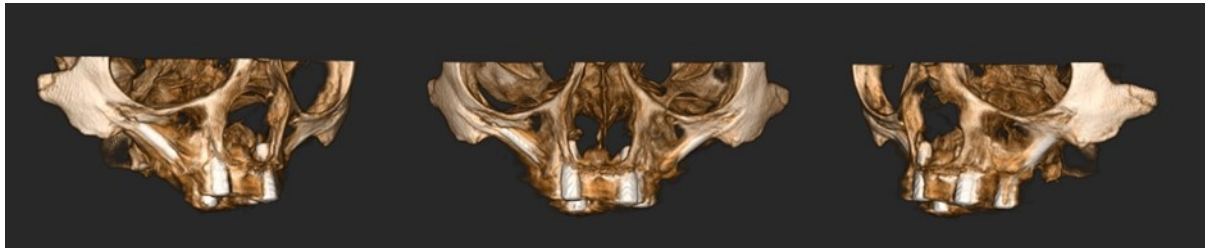


Fig.5 – Post-operative 3D maxilla bone reconstruction

Conclusions

The development of the zygomatic implant was performed with the aim of rehabilitating patients with large facial mutilations such as hemimaxillectomy, tumor resection, traumas or genetic defects. This procedure has been gaining an increasing number of indications, which include extensive maxillary reabsorption (especially in the posterior sector), cleft palate, dehiscence of bone graft or when it is contraindicated ^(12,22,23) and now Down Syndrome patients.

The advantages of this technique are clear: a) time of surgery is significantly reduced, in addition to the rehabilitation of the patient in only one surgery, and in some cases the patient may be able to carry immediate loading; b) success rates of osseointegration with zygomatic implants are over 90% compared to 75% success rates in maxillary sinus grafting techniques without the occurrence of potential complications associated with the collection and application of the bone graft ^(12,22,23); c) equivalent laboratory time or prosthetic tests when compared to standard implants ⁽¹²⁾.

Simple guidelines and protocols for treating and educating Down Syndrome patients with dental implants must be established with the precious help of the caretakers that must be fully involved in the reinforcement of oral hygiene, as the dental practitioners cannot verify whether postoperative instructions are followed appropriately ⁽⁵⁾.

Conflict of Interest

The author declares that there is no conflict of interest regarding the publication of this article.

References

1. Diz P., Scully C., Sanz M., Dental Implants in the medically compromised patient. *Journal of Dentistry*, 2013. 41:195-206.
2. Durham M., Brindis M., Egbert N., Halpern L.R., Complex Dental Implant Cases. *Oral Maxillofacial Surg Clin N Am*, 2019. 219-249.
3. Najeeb S., Khurshid Z., Siddiqui F., Zohaib S., Zafar M.S., Outcomes of dental implant therapy in patients with Down Syndrome: a systematic review. *The Journal of Evidence Based Dental Practice*, 2017. 17:317-323.
4. Glass T.J., Connor N.P., Digastric Muscle Phenotypes of the Ts65Dn Mouse Model of Down Syndrome. *Plos One*, 2016. 11:1-15.
5. Saponaro P.C., Deguchi T., Lee D.J., Implant therapy for a patient with Down Syndrome and oral habits: A clinical report. *The Journal of Prosthetic Dentistry*, 2016. 116:320-324.
6. van Marrewijk D.J.F., van Stiphout M.A.E., Reuland-Bosma W., Bronkhorst E.M., Ongkosuwito E.M., The relationship between craniofacial development and hypodontia in patients with Down syndrome. *European Journal of Orthodontics*, 2016. 38:178-183.

7. Najeeb S., Khurshid Z., Siddiqui F., Zohaib S., Zafar M.S., Outcomes of dental implant therapy in patients with Down Syndrome: a systematic review. *The Journal of Evidence Based Dental Practice*, 2017. 17:317-323.
8. Schmidt P., Goedicke-Padligr G., Schulte A.G., Benz K., Jackowski J., Implant-supported prosthetic rehabilitation of a senescent patient with Down syndrome. *Quintessence Int*, 2020. 51, 170-177.
9. Ekfeldt A., Zellmer M., Carlsson G.E., Treatment with implant-supported fixed dental prostheses in patients with congenital and acquired neurologic disabilities: a prospective study. *Int J Prosthodont*, 2013. 26:517-524.
10. Karoussis I.K., Brägger U., Salvi G.E., Bürgin W., Lang N.P., Effect of implant design on survival and success rates of titanium oral implants. a 10-year prospective cohort study of the ITI dental implant system. *Clin Oral Implants Res*, 2004. 15:8-17.
11. Rigolizzo M, Camilli J, Francischone C, Padovani C, Brånemark P-I., Zygomatic bone: anatomic bases for osseointegrated implant anchorage. *Int J Oral Maxillofac Implants*, 2005. 20(3):441-447.
12. Ferrara E, Stella J., Restoration of the edentulous maxilla: The case for the zygomatic implants. *J Oral Maxillofac Surg*, 2004. 62:1418-1422.
13. Malevez C, Daelemans P, Adriaessens P, Durdu F., Use of zygomatic implants to deal with resorbed posterior maxillae. *Periodontology*, 2003. 33:82-89.
14. Kato Y., Kizu Y., Tonogi M., Ide Y., Yamane G., Internal structure of zygomatic bone related to zygomatic fixture. *J Oral Maxillofac Surg*, 2005. 63(9):1325-1329.
15. Bedrossian, E., Stumpel L., Beckely M.L., Indresano T., The zygomatic implant: preliminary data on treatment of severely resorbed maxillae. A clinical report. *Int J Oral Maxillofac Implants*, 2002. 17(6):861-865.
16. Malevez, C., Abarca M., Durdu F., Daelemans P., Clinical outcome of 103 consecutive zygomatic implants: a 6-48 months follow-up study. *Clin Oral Implants Res*, 2004. 15(1):18-22.
17. Patel, R.R., Brook M.I., Wragg P.F., Zygoma implants or sinus augmentation and conventional implants? *Clin Oral Implants Res*, 2003. 14:
18. Stevenson, A.R., Austin B.W., Zygomatic fixtures-the Sydney experience. *Ann R Australas Coll Dent Surg*, 2000. 15:337-339.
19. Brånemark, P.I., Gröndahl K., Öhrnell L.O., Nilsson P., Petruson B., Svensson B., Engstrand P., Nannmark U., Zygoma fixture in the management of advanced atrophy of the maxilla: technique and long-term results. *Scand J Plast Reconstr Surg Hand Surg*, 2004. 38(2):70-85.
20. Hirsch, J.M., Öhrnell L.O., Henry P.J., Andreasson L., Brånemark P.I., Chiapasco M., Gynther G., Finne K., Higuchi K.W., Isaksson S., Kahnberg K.E., Malevez C., Neukam F.W., Sevetz E., Urgell J.P., Widmark G., Boling P., A clinical evaluation of the Zygoma fixture: one year of follow-up at 16 clinics. *J Oral Maxillofac Surg*, 2004. 62(9 Suppl 2):22-9.
21. Duarte F., Ramos C., Silva JN., Immediate function with four Zygomatic implants in patients with extreme maxillary atrophy – Case Series. *JSPIR* 2019; 1(2):51-55
22. Malevez C., Daelemans P., Adriaessens P., Durdu F., Use of zygomatic implants to deal with resorbed posterior maxillae. *Periodontology*, 2003. 33: 82-89.
23. Vrielinck L., Politis C., Schepers S., Pauwels M., Naert I., Image-based planning and clinical validation of zygoma and pterygoid implant placement in patients with severe bone atrophy using customized drill guides. Preliminary results from prospective clinical follow-up study. *Int J Oral Maxillofac Surg*, 2003. 32:7-14.

Citation: Fernando Duarte, Luis Pinheiro, Carina Ramos and João Neves Silva. “Rehabilitation of Down Syndrome with Zygomatic Implants-Case Report”. *SVOA Dentistry* 2:1(2021) pages 15-19.

Copyright: © 2021 All rights reserved by Fernando Duarte et al. This is an open access article distributed under the Creative Commons Attribution License, which permits unrestricted use, distribution, and reproduction in any medium, provided the original work is properly cited.